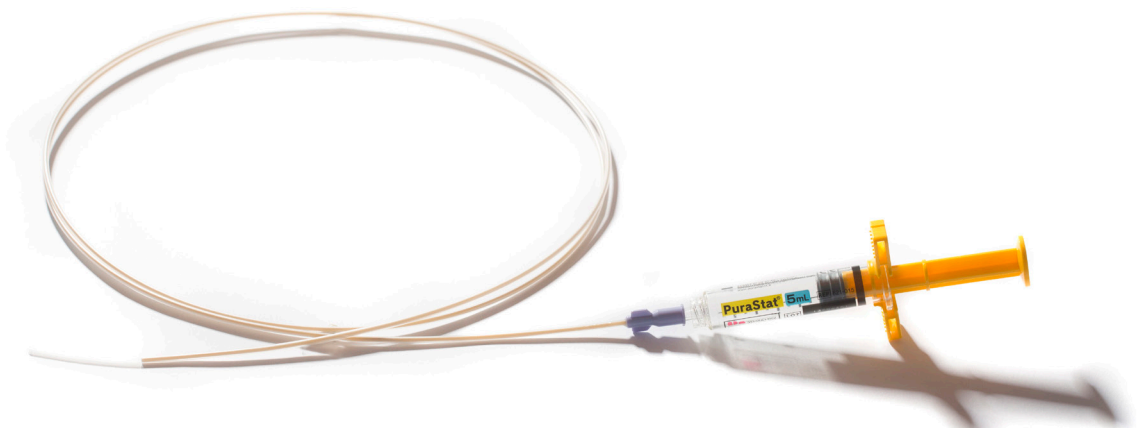




PuraStat®
Clear haemostatic control⁽¹⁾

Case Reports:
Gastrointestinal Procedures



Contents

Volume 1:	2
Experience of PuraStat® During Resection of a Large Circumferential, recto-sigmoid polyp	
<i>Professor Pradeep Bhandari, Queen Alexandra Hospital, Endoscopy Department, Portsmouth, United Kingdom</i>	
Volume 2:	3
Haemostasis with PuraStat® During ESD/EMR Procedure	
<i>Professor Pradeep Bhandari, Queen Alexandra Hospital, Endoscopy Department, Portsmouth, United Kingdom</i>	
Volume 3:	4
Haemostasis with PuraStat® During Polyp Resection in Patients Using Anti-Aggregants	
<i>Dr Víctor M Aguilar Urbano, Hospital El Ángel (Málaga), Spain</i>	
Volume 4:	5
Haemostasis with PuraStat® in Papillectomy	
<i>Professor Jens Tischendorf, M.D., Department of Internal Medicine und Gastroenterology, Rhein-Maas Hospital, Würselen, Germany</i>	
Volume 5:	6
Using PuraStat® on Post-Surgical Dehiscence	
<i>Doctor Claudio Zulli, GI and Endoscopy Staff, Endoscopy Unit, AOUI San Giovanni di Dio e Ruggi d'Aragona, Mercato San Severino, Salerno, Italy</i>	

PuraStat®

Clear haemostatic control ⁽¹⁾

gastrointestinal case report | Vol. 1

Experience of PuraStat® During Resection of a Large Circumferential, recto-sigmoid polyp

CASE PRESENTATION

DIAGNOSIS

Carpet adenoma of rectum (Size: Circumferential lesion from dentate line to 17cm in rectum)

PROCEDURE

- ▶ Knife Assisted snare Resection (KAR): An ESD knife was used for marking the edges of the polyp and performing circumferential mucosal incision around the lesion with some submucosal dissection before snare resecting it in multiple pieces. An electro-surgical coagulation forceps was occasionally used for haemostasis.
- ▶ PuraStat was applied, with the catheter specially designed for the syringe, a total of 4 times to the bleeding vessels in the EMR base during procedure and good haemostasis was observed. Approximately 8.5 ml of PuraStat was used in total.
- ▶ Histology: Adenoma with low grade dysplasia.

POSTOPERATIVE COURSE

Repeat endoscopy at 2 weeks showed very healthy, almost healed EMR scar with mild narrowing of the lumen. Prophylactic dilatation was performed twice with no recurrence at 3 months.

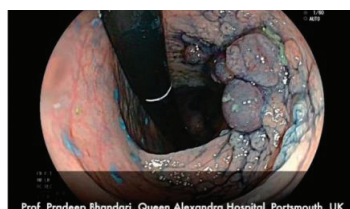

Fig. 1: Carpet adenoma of rectum

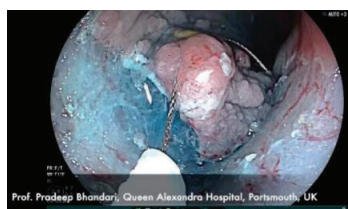

Fig. 2: Snare resection of the lesion

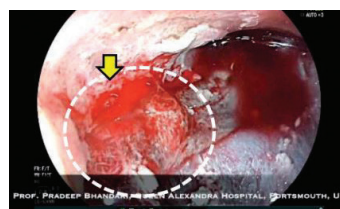


Fig. 3: White dot circle: transparent PuraStat covered the bleeding site
Yellow arrow: bleeding point

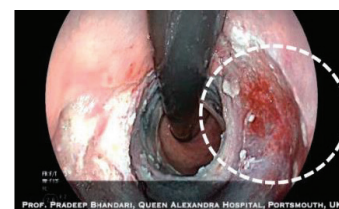


Fig. 4: Haemostasis was achieved

FEEDBACK ON PURASTAT USAGE



“PuraStat is very easy to deliver and to handle. PuraStat stops oozing and slows down brisk bleeds. It is a transparent gel which does not compromise endoscopic views after application as compared to other spray powders. This allows endoscopist to apply additional haemostatic therapy if necessary. The standard therapy for haemostasis control such as electrocautery introduces a thermal injury to the bowel wall and carries the risk of causing perforation. Furthermore, it requires precise targeting of the bleeding vessel which can be very difficult during active bleeds.”

PuraStat can be applied in the general area of bleeding and does not require precise application to the exact point of bleeding. It was really surprising to see enhanced healing and formation of soft scar at the EMR site, 15 days post procedure.”

Pradeep Bhandari, Professor

Queen Alexandra Hospital, Endoscopy Department
Portsmouth, United Kingdom

PuraStat®

Clear haemostatic control ⁽¹⁾

gastrointestinal case report | Vol. 2

Haemostasis with PuraStat® During ESD/EMR Procedure

CASE PRESENTATION 1

DIAGNOSIS

Barrett's oesophagus C0M5 (Circumferential extent and Maximum extent of metaplasia) and a neoplastic lesion within the Barrett's segment

PATIENT DEMOGRAPHICS

Male, 63 years old

PROCEDURE

- ▶ Underwent ESD for 40 mm nodule
- ▶ Mucosal oozing and bleeding from a visible vessel encountered during procedure and haemostasis achieved with 4 ml of PuraStat
- ▶ Post ESD histology:
 - ▶ Residual tumor (R) classification: R0
 - ▶ well differentiated intramucosal cancer (tumor extension: pT1aM2) with no lympho-vascular invasion

POSTOPERATIVE COURSE

Uneventful
No delayed bleeding or perforation

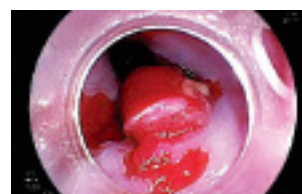

Fig. 1: Barrett's intramucosal cancer

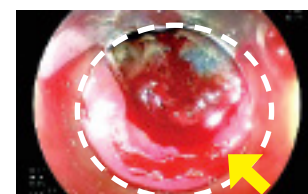


Fig. 2: Bleeding during ESD. Yellow arrow indicates bleeding point. White dot circle indicates resected area

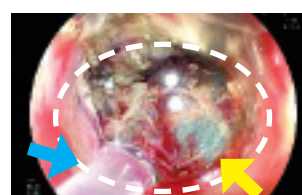


Fig. 3: White dot circle: transparent PuraStat covered the bleeding site: Yellow arrow: bleeding point; Blue arrow: tip of the catheter

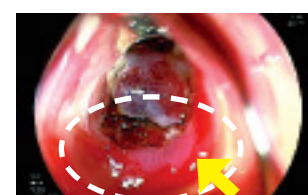


Fig. 4: Haemostasis achieved

CASE PRESENTATION 2

DIAGNOSIS

A 20 mm sigmoid polyp scarred from previous unsuccessful attempts at resection

PATIENT DEMOGRAPHICS

Female, 71 years old

PROCEDURE

- ▶ Knife Assisted snare Resection (KAR) was performed following 80% circumferential dissection
- ▶ Mucosal bleeding encountered during dissection Haemostasis achieved with 2 ml of PuraStat

POSTOPERATIVE COURSE

Uneventful
No delayed bleeding or perforation

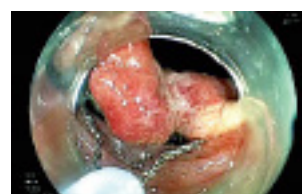

Fig. 1: Knife assisted snare resection of sigmoid polyp

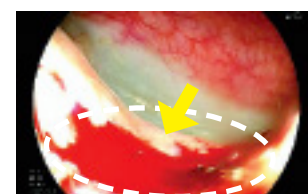


Fig. 2: Bleeding during KAR. Yellow arrow indicates bleeding point. White dot circle indicates resected area

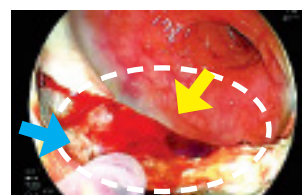

Fig. 3: White dot circle: transparent PuraStat covered the bleeding site: Yellow arrow: bleeding point; Blue arrow: tip of the catheter

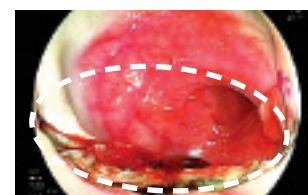


Fig. 4: Haemostasis achieved

FEEDBACK ON PURASTAT USAGE



“Haemostatic control offered by PuraStat made Barrett's ESD safer by reducing the need for coagulation current on the esophageal ESD base.”

“Scarred polyps can be very difficult to resect with significant risk of bleed and perforation. PuraStat is helping reduced the immediate risk.”

Pradeep Bhandari, Professor

Queen Alexandra Hospital, Endoscopy Department Portsmouth, United Kingdom

”

“

PuraStat®

Clear haemostatic control ⁽¹⁾

gastrointestinal case report | Vol. 3

Haemostasis with PuraStat® During Polyp Resection in Patients Using Anti-Aggregants

CASE PRESENTATION 1

DIAGNOSIS

Sigmoid polyp in patient receiving dual antiplatelet therapy. Restenosis after prior stent placement 6 months ago. Patient requiring urgent surgery due to caecum neoplasia (Fig. 1).

PATIENT DEMOGRAPHICS

Male, 72 years old

PROCEDURE

- ▶ Injection of diluted adrenalin in the base of the lesion and then resection with a braided polypectomy loop
- ▶ 1.5 ml of PuraStat was applied over the bleeding scar, achieving a good haemostasis (Fig. 2)
- ▶ Histology: Tubular villous adenoma with high grade dysplasia and foci of intramucosal carcinoma

POSTOPERATIVE COURSE

The patient showed good progress without manifestation of bleeding and anemia. Endoscopic follow up after 2 months without alterations.

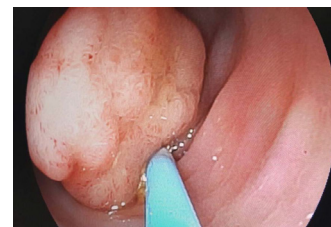


Fig.1 : Obstructive sigmoid polyp

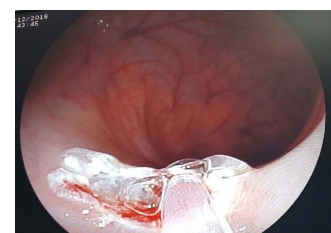

Fig. 2 : Application of PuraStat over the bleeding scar

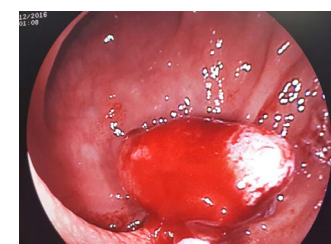


Fig. 3: Bleeding polyp in left colon

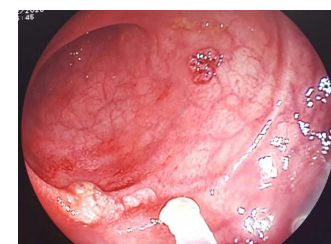


Fig. 4: Haemostasis achieved after application of 2 ml PuraStat. There was no remaining active bleeding in the resected area

CASE PRESENTATION 2

DIAGNOSIS

Active bleeding polyp in left colon (Fig. 3) Patient suffering from anemia and episodes of angina pectoris. Antiplatelet medication due to stent placement after heart attack 4 months ago

PATIENT DEMOGRAPHICS

Male, 54 years old


PROCEDURE

- ▶ Resection with polypectomy loop
- ▶ After application of 2 ml PuraStat haemostasis was achieved in the resected area (Fig. 4)
- ▶ Histology: Tubular villous adenoma with high grade dysplasia

POSTOPERATIVE COURSE

The patient was discharged showing good progress without anemia or active bleeding having occurred. Endoscopic follow up after 2 months without complications.

FEEDBACK ON PURASTAT USAGE



“

“Due to the transparency and the fact that it is easy-to-use, PuraStat is well applicable to treat and prevent bleedings⁽¹⁾ in the sub-mucosa due to possible residual lesions”

”

Dr. Víctor M Aguilar Urbano
Hospital El Ángel (Málaga), Spain

PuraStat®

Clear haemostatic control ⁽¹⁾

gastrointestinal case report | Vol. 4

Haemostasis with PuraStat® in Papillectomy

CASE PRESENTATION

DIAGNOSIS

Adenoma of the major duodenal papilla

PATIENT DEMOGRAPHICS

- Male, 54 years old
- Incidental finding of an adenoma of major duodenal papilla (Fig. 1)
- Histology: tubulo-villous adenoma with low grade dysplasia

PROCEDURE

- ▶ Endoscopic resection of the adenoma with snare papillectomy and prophylactic implantation of a pancreatic stent (Fig. 2)
- ▶ Haemorrhagic shock on the following day caused by an arterial bleeding at the resection site occurred (Fig. 3)
- ▶ Injection of 6 ml adrenaline (1:10000) and implantation of a stent in the bile duct was consecutively performed (Fig. 4)
- ▶ Because of persistent bleeding 1 ml PuraStat was applicated and haemostasis could be achieved after 45 seconds (Fig.5); (Fig. 6)

POSTOPERATIVE COURSE

2 days after following application of PuraStat a clear resection site was observed an both stents could be removed

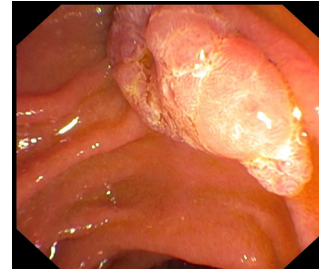


Fig.1 : Adenoma of the duodenal major papilla

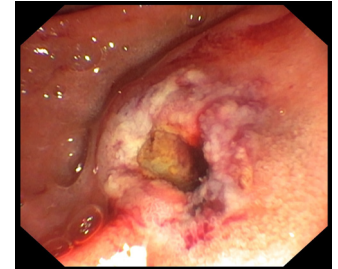


Fig. 2 : Unremarkable resection site after endoscopic papillectomy

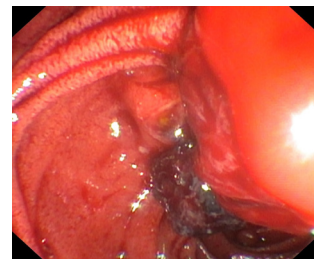


Fig. 3 : Severe arterial bleeding on the following day

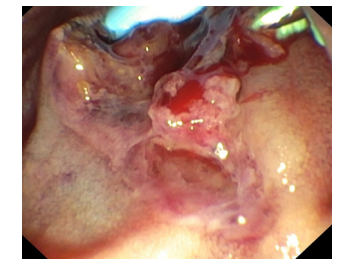

Fig. 4 : Persistent bleeding despite of injection of adrenaline (1:10000)

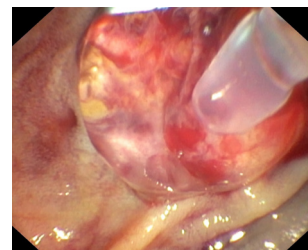


Fig. 5 : Transparent PuraStat covered the bleeding site. Complete haemostasis was achieved after 45 seconds

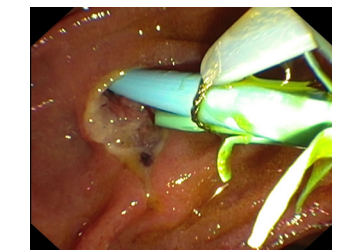


Fig. 6 : Clear bleeding site two days later. Endoprotheses (pancreatic and bile duct) could be removed

FEEDBACK ON PURASTAT USAGE



“

“PuraStat is very helpful new tool in haemostasis that allows successful application also in such special bleeding sites as the duodenal papilla where clipping is very difficult/dangerous because of the orifice of pancreatic and bile duct.

PuraStat is very easy to use.”

Professor Jens Tischendorf, M.D.

*Department of Internal Medicine und Gastroenterology
Rhein-Maas Hospital, Würselen, Germany*

”

PuraStat®

Clear haemostatic control ⁽¹⁾

gastrointestinal case report | Vol. 5

Using PuraStat® on Post-Surgical Dehiscence

CASE PRESENTATION

DIAGNOSIS

Hypertonic anal sphincters

PATIENT DEMOGRAPHICS

- Male, 54 years old
- Stapled haemorrhoidectomy (Longo procedure)
 - After 4 weeks, massive rectal bleeding, causing severe anaemia
 - Topic steroidal and mesalazine therapy was performed (1 week)
 - No improvement
 - Digital rectal examination showed hypertonic anal sphincters and bright red stool

PROCEDURE

- ▶ A recto-sigmoidoscopy was immediately performed, showing a 3 cm dehiscence caused by impaired or delayed wound healing.
- ▶ During the same procedure, PuraStat was applied to the dehiscence area. This allowed the creation of a film, protecting the submucosal layers. 3 ml of PuraStat was used.
- ▶ No bleeding during procedure.

POSTOPERATIVE COURSE

No post-procedural bleeding or other complications were observed. Four weeks after the first treatment, the patient underwent a new recto-sigmoidoscopy. This showed a complete mucosal healing of the dehiscence. Patient reported no recurrence of rectal bleeding or tenesmus.

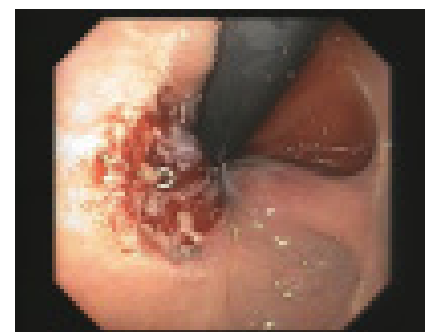


Fig. 1: Recto-sigmoidoscopy showing the bleeding dehiscence

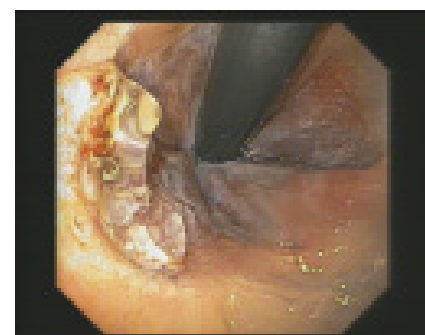

Fig. 2: PuraStat application onto the dehiscence area

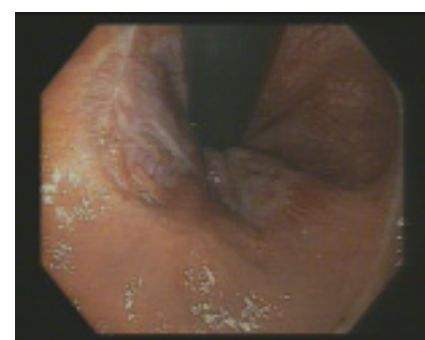

Fig. 3: Recto-sigmoidoscopy showing a complete mucosal healing of the dehiscence

FEEDBACK ON PURASTAT USAGE



“

“PuraStat is a very easy to use endoscopic device, with a quick haemostatic effect and a full transparency allowing a clear vision on bleeding or tissue. Transparency of PuraStat maintains a clear view and full control, increasing accuracy and safety. Our case shows a new possible field of application for PuraStat. This peptide-based matrix seems to have tissue regenerative properties, as demonstrated on cell cultural media and in dental bone.”

”

Dr Claudio Zulli

GI and Endoscopy Staff, Endoscopy Unit, AOUI San Giovanni di Dio e Ruggi d'Aragona, Mercato San Severino, Salerno, Italy



PuraStat®

Clear haemostatic control⁽¹⁾

Case Reports: Gastrointestinal Procedures

Want to find out more about PuraStat?

Contact Us:

More information at:



PuraStat® is indicated for haemostasis in the following situations encountered during surgery, when haemostasis by ligation or standard means is insufficient or impractical:

- Bleeding from small blood vessels and oozing from capillaries of the parenchyma and surrounding tissues of solid organs
- Oozing from vascular anastomoses to native or artificial vessels, on the surface of blood vessels and surrounding tissues
- Bleeding from small vessels and oozing from capillaries of the GI tract following surgical procedures and surrounding tissues.

PuraStat is also indicated for the reduction of delayed bleeding following gastrointestinal endoscopic submucosal dissection (ESD) procedures in the colon.



3-D Matrix Europe SAS

11 chemin des Petites Brosses
69300 Caluire-et-Cuire-FRANCE
Tel: +33 (0)4 27 19 03 40
infoeu@puramatrix.com | www.3dmatrix.com

(1) PuraStat IFU-007 Rev 2

PuraStat is a class III medical device CE marked according to European council directive 93/42/EEC on medical devices and its relatives

