

one & done

Ovesco OTSC® – The ultimate hemostasis device*

*New data: OTSC® superior to TAE

OTSC® superior to TAE in refractory peptic ulcer bleeding – reducing mortality and ICU stay.

Compared to patients treated with transcatheter arterial embolization (TAE) for refractory peptic ulcer bleedings, OTSC® showed higher efficacy (72.5 % vs. 62.5 % ($p = 0.474$)) and significantly reduced length of stay in ICU (4.9 vs. 9.2 days $p = 0.009$) as well as a significantly reduced in-house mortality (5.0 % vs. 22.5 % ($p = 0.048$)).¹




Scan here to read the full
summary of the lecture

¹ Kuellmer A, Mangold T, Bettinger D, Maruschke L, Wannhoff A, Caca K, Wedi E, Jung C, Kleemann T, Schulz T, Thimme R, Schmidt A. **OTSC vs TAE as salvage therapy for refractory peptic ulcer bleeding** Congress lecture, UEG Week Virtual 2020 (2020, October 11)



stentfix OTSC[®]

Preventing stent migration.



Stent fixation made simple

The stentfix OTSC[®] System is the innovative solution for stent fixation in the digestive tract. It is a specially designed OTSC[®] System and labeled for the fixation of self-expandable metallic stents (SEMS).

The round design of the stentfix OTSC[®] clip adapts perfectly to the gastrointestinal anatomy. Due to the modified cap shape, stentfix OTSC[®] can easily be aligned to the stent opening for optimal stent mesh and tissue capture by the clip.

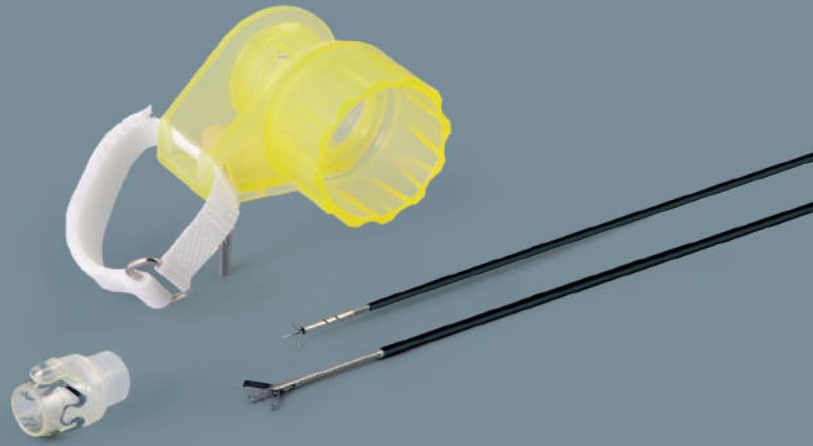The compact design of the stentfix OTSC[®] System also allows the passage through a stent (from Ø 18 mm), therefore, fixation is possible either on the proximal or distal end.



OTSC[®]
STENTFIX



o v e s c o
innovation in scope



OTSC[®] System.....

saving lives[®]

The innovative clipping system for flexible endoscopy



The OTSC® System stands for superior clinical efficacy^{1,2}, easy and quick application³ and cost effectiveness⁴.

The OTSC® System is used in flexible endoscopy for

- acute bleeding
- wall closure
- closure of chronic lesions
- management of complications after endoscopic or surgical procedures

..... OTSC® System

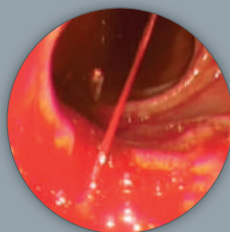
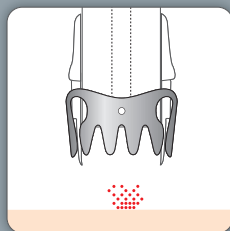
The OTSC® System is an innovative clipping system to be applied via flexible endoscopes. It offers the physician unique features superior to any other device:

- dynamic compression, continuous adaption to tissue thickness
- larger volume of tissue secured
- higher stability at the lesion site
- minimal strain on surrounding tissue

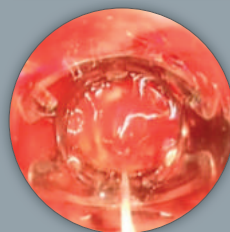
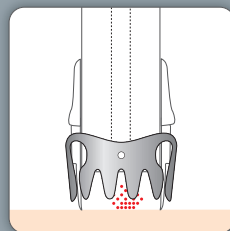
The exceptional features and therapeutic functions of the OTSC® System are based on its unique material and design: the superelastic Nitinol® is biocompatible, MRI conditional, and, if needed, even suited to be applied as a long-term implant.

..... Application

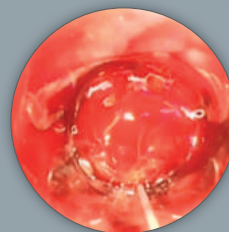
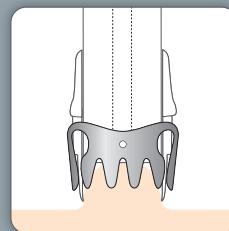
Hemostasis



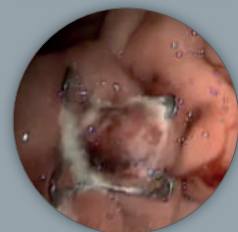
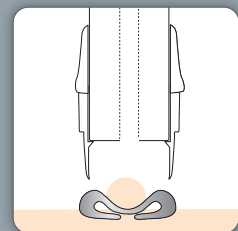
Target lesion with OTSC® System.



Bring OTSC® cap in contact with tissue.



Suction target tissue into OTSC® cap.



Apply OTSC® clip by turning the hand wheel.

Hemostasis of an arterial bleeding, source: Prof. Dr. Chiu, Prince of Wales Hospital, Hong Kong SAR, China

1 Wedi E, Fischer A, Hochberger J, Jung C, Orkut S, Richter-Schrag HJ. Multicenter evaluation of first-line endoscopic treatment with the OTSC in acute non-variceal upper gastrointestinal bleeding and comparison with the Rock all cohort: the FLETRock study. *Surg Endosc.* 2018 Jan;32(1):307-314. doi:10.1007/s00464-017-5678-7. Epub 2017 Jun 27.

2 Schmidt A, Gölder S, Goetz M, Meining A, Lau J, von Delius S, Escher M, Hoffmann A, Wiest R, Messmann H, Kratt T, Walter B, Bettinger D, Caca K. Over the Scope Clips Are More Effective Than Standard Endoscopic Therapy for Patients With Recurrent Bleeding of Peptic Ulcers. *Gastroenterology.* 2018 Sep;155(3): 674-686.e6. doi:10.1053/j.gastro.2018.05.037. Epub 2018 May 24

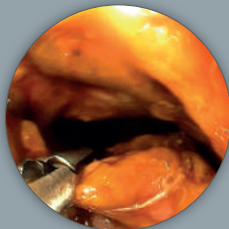
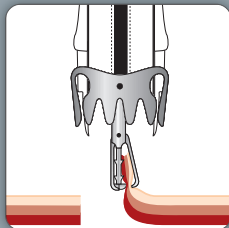


The use of the OTSC® System is intuitive and easy, very similar to other devices based on the application cap principle. The application cap is mounted to the tip of the endoscope. By turning the handwheel, the thread is tightened and the clip is applied. It is compatible with commercially available endoscopes. A variety of different sizes and combinations are available for commonly used endoscopes.

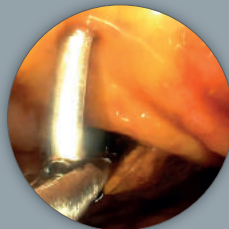
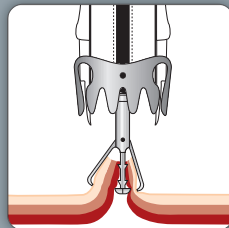
Our application aids allow easier positioning of lesions: the OTSC® Anchor (e.g. fistula or ulcer bleeding treatment) and the OTSC® Twin Grasper® (e.g. perforation closure) assist you in approximating tissue precisely into the cap.

All OTSC® products are disposable and designed for single patient use.

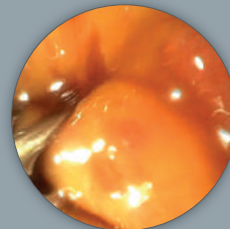
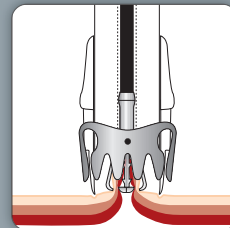
Perforation closure



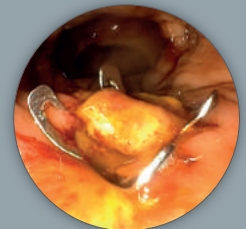
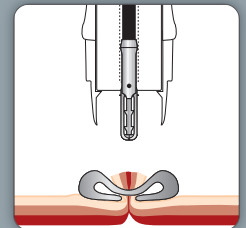
Grasp first perforation edge with one of the two OTSC® Twin Grasper® jaw parts.



Grasp opposite perforation edge with second jaw part.



Retract perforation into cap (OTSC® Twin Grasper® must be fully inside cap).



Apply clip and release OTSC® Twin Grasper®.

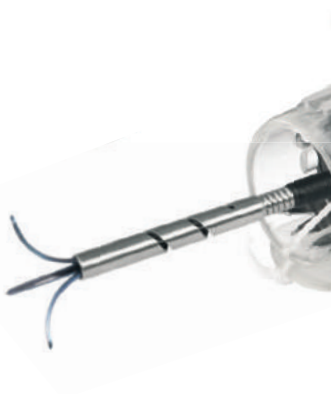Closure of a perforation in the rectum, source: Dr. Mauro Manno & Dr. Paola Soriani, UOSD Endoscopia Digestiva Area Nord, Azienda USC di Modena, Ospedale di Carpi e Mirandola, Italy

3 Kato M, Jung Y, Gromski MA, Chuttani R, Matthes K. Prospective, randomized comparison of 3 different hemoclips for the treatment of acute upper GI hemorrhage in an established experimental setting. *Gastrointest Endosc.* 2012 Jan;75(1): 3-10. doi:10.1016/j.gie.2011.11.003

4 Küllmer A, Behn J, Glaser N, Thimme R, Caca K, Schmidt A. Over-the-scope clips (OTSC) are cost-effective in recurrent peptic ulcer bleeding. *United European Gastroenterol J.* 2019 Nov; 7(9): 1226-1233.



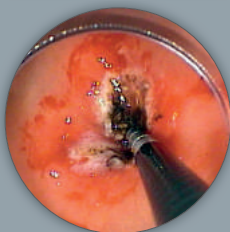
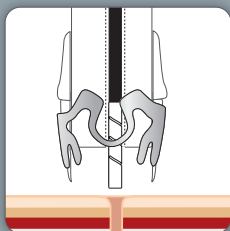
OTSC®
ANCHOR



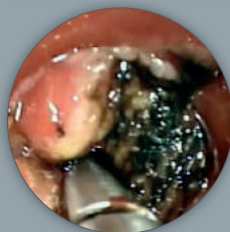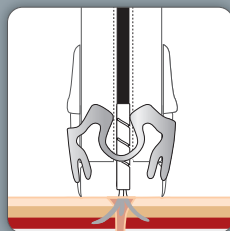
OTSC®
TWIN GRASPER®



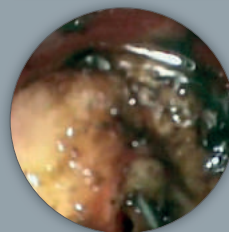
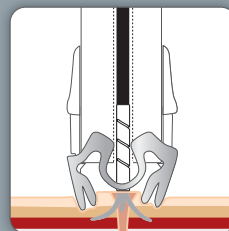
Fistula closure



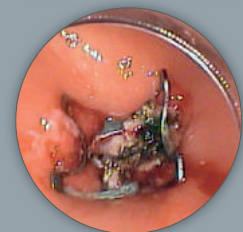
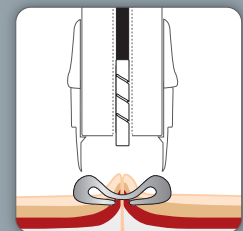
Target fistula opening, position the OTSC® Anchor and fix tissue.



Align OTSC® cap to the fistula opening by pulling the anchor and advancing endoscope.



Mobilize tip of OTSC® Anchor shaft into cap; anchor spikes may remain external.



Apply clip; release OTSC® Anchor from tissue.

Closure of a PEG fistula, source: Dr. Thomas Kratt, Universitätsklinikum Tuebingen, Germany

Details and components

The OTSC® System consists of an applicator cap with a mounted clip, handwheel and thread retriever. The OTSC® System is available in the following variety of cap sizes and clip designs to provide secure application regardless of the anatomical situation and endoscope type.

- 4 different cap and corresponding clip sizes
- 2 different cap depths for capturing more or less tissue
- 3 different teeth shapes suitable for different areas of application



OTSC® Version	mini	11	12	14
Endoscope diameter Ø [mm]	8.5–10	8.5–11	10.5–12	11.5–14
Depth of cap	3 mm	11/3a¹ (100.03)*	12/3a¹ (100.05)*	14/3a² (100.07)*
		11/3t¹ (100.04)*	12/3a² (100.28)*	14/3t² (100.08)*
6 mm	mini/6a¹ (100.01)*	11/6a¹ (100.09)*	12/6a¹ (100.11)*	14/6a² (100.13)*
		11/6t¹ (100.10)*	12/6a² (100.30)*	14/6t² (100.14)*
			12/6t¹ (100.12)*	
			12/6t² (100.31)*	
			12/6gc¹ (100.27)*	
Max. outer diameter Ø [mm]	14.6	16.5	17.5	21

* (ref. no.) ¹ thread length 165 cm ² thread length 220 cm



type a

blunt teeth, primarily compression effect



type t

teeth with small spikes, compression and anchoring effect



type gc

elongated teeth with spikes, application: closure of gastric wall

Application aid

There are two instruments available to enable a more effective application. These can be inserted next to the thread in the same working channel.



For better approximation of tissue especially when hard or fibrotic (e.g. fistulae, chronic ulcer), OTSC® Anchor 220tt especially for thin tissue.

	OTSC® Anchor	OTSC® Anchor 220tt
ref. no.	200.10	200.11
working length	1650 mm	2200 mm
max. Ø	2.4 mm	2.4 mm
needle width	12 mm	9 mm
stitch depth	4 mm	2–2.5 mm



For easier approximation of gaping edges of a lesion (e.g. perforation).

	OTSC® Twin Grasper®	
ref. no.	200.44	200.45
working length	1650 mm	2200 mm
max. Ø	2.6 mm	2.6 mm

Ovesco Endoscopy AG
Friedrich-Miescher-Strasse 9
72076 Tuebingen
Germany

Telefon +49(0)7071 96528-160
Fax +49(0)7071 96528-260
E-Mail service@ovesco.com





O V E S C O
innovation in scope

Expanded endoscope compatibility &
optimized clip deployment



stentfix OTSC® System.....

Preventing stent migration

- Clip design adapts to the wall
- Allows proximal and distal fixation
- Dedicated cap shape for easy positioning





OTSC®
STENTFIX

o o o o v e s c o



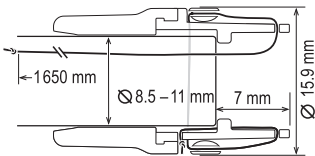
..... stentfix OTSC® System

The stentfix OTSC® System is the innovative solution for stent fixation in the digestive tract. It is a specially designed OTSC® System and labeled for the fixation of self-expandable metallic stents (SEMS).

The round design of the stentfix OTSC® clip adapts to the gastrointestinal anatomy. Due to the modified cap shape, stentfix OTSC® can easily be aligned to the stent opening for optimal stent mesh and tissue capture by the clip.

The compact design of the stentfix OTSC® System also allows the passage through a stent (from Ø 18 mm), therefore, fixation is possible either on the proximal or distal end.

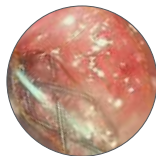
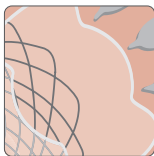
Measurements



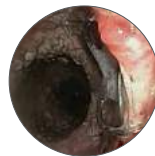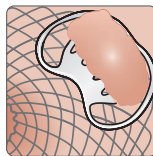
stentfix OTSC® System Set (ref. no. 100.50)

..... Application

Proximal fixation of the stent – Clinical example*

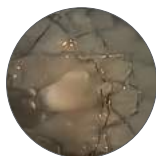
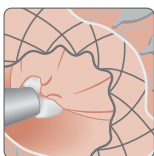


Align clip tooth rows parallel to stent opening, so that tissue and stent mesh are evenly captured.
Mobilization of tissue by suction.

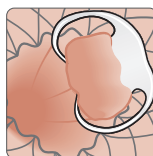

Optimal adaptation of the clip to the wall.

Distal fixation of the stent – Demonstration on Ex-vivo model



Align clip tooth rows parallel to stent opening, so that tissue and stent mesh are evenly captured.
Mobilization of tissue by grasping below the stent meshes.



Optimal adaptation of the clip to the wall.

* Source: Dr. Massimo Conio, Sanremo Hospital, Italy

Ovesco Endoscopy AG
Friedrich-Miescher-Strasse 9
72076 Tuebingen
Germany

Phone +49 (0) 7071 96528-160
Fax +49 (0) 7071 96528-260
E-Mail service@ovesco.com



Ovesco Endoscopy AG is a medical device company specializing in the fields of flexible endoscopy and endoluminal surgery. Ovesco develops, manufactures, and markets innovative products for the treatment of gastrointestinal disease. Ovesco products stand for therapeutic efficacy and efficient application.

WWW.OVESCO.COM

clinical bulletin

OTSC[®] System

volume 3 | hemostasis

OTSC[®] for hemostasis

the OTSC[®] System



OTSC[®] – the ultimate hemostasis device (one & done)

The clinical benefit of the OTSC[®] System has been proven within two multicenter studies:

OTSC[®] in first-line therapy significantly reduces re-bleeding risk and re-bleeding-associated mortality in upper gastrointestinal bleeding (UGIB) (FLETROCK evaluation¹). Compared to Rockall's validated prediction, re-bleeding risk and re-bleeding-associated mortality were significantly reduced from 53.2% to 21.4% ($p < 0.001$) and 27.9% to 10.9% ($p = 0.011$), respectively in high-risk Rockall score (score 8) patients treated with the OTSC[®].

Compared to former standard therapy, OTSC[®] significantly improves the clinical outcome of hemostasis in patients with recurrent ulcer bleeding (STING trial²). Patients were treated with either OTSC[®] therapy or therapy with conventional endoclips or thermal coagulation (each plus injection). Successful hemostasis was achieved by OTSC[®] over former standard therapy in 93.9% vs 57.6% of patients ($p = 0.001$).

Overview of the OTSC[®] System

The OTSC[®] System is an innovative product used in flexible endoscopy for hemostasis and for closure of acute and chronic lesions.

The OTSC[®] consists of a transparent applicator cap with a mounted Nitinol[®] clip, thread, thread retriever and handwheel for clip release. The set-up and application of the OTSC[®] System is simple and quick. The procedure combines the following benefits:

- Securing of large tissue volume
- Stable tissue capture and durable effect at the site of intervention with dynamic compression
- Simple and faster application than other techniques through "one & done" placement



A current meta-analysis using a pooled-proportion analysis of published literature has shown clinical success rates of 87.5% in hemostasis, 81.4% in closure of acute lesions and 63% in closure of chronic lesions and fistulae³. Further details on clinical data of the OTSC[®] System can be found on pages 4–6 of this bulletin.

Properties and sizes of OTSC[®] application caps and clips

The OTSC[®] System is available in a variety of cap sizes and clip designs to provide secure hemostasis regardless of the anatomical situation and endoscope type. For hemostasis in the upper GI tract, the cap sizes (OTSC[®] versions) mini, 11 and 12 are used; the cap size 14 is usually used for colonoscopes.

The OTSC[®] application cap creates distance between the tip of the endoscope and the gastrointestinal wall. This distance provides visibility and allows the cap to enfold sufficient tissue, with the vessel in the center. With suction and flushing, the OTSC[®] cap can thereby support tissue cleansing and simplifies the visualization of the bleeding source. The different cap sizes (mini, 11, 12, & 14) correspond to maximum diameters of the endoscope you can use and allow appropriate cap selection based on the anatomical situation you are faced with. The new mini OTSC[®] System is designed for cases of difficult access and also fits on pediatric endoscopes. There are two cap depths, shallow (3 mm) vs deep (6 mm). The shallow cap provides unrestricted endoscopic visibility and maneuverability and is ideal for small lesions or thin tissue areas. The deeper cap enables the user to retract and clip a larger amount of tissue.

OTSC [®] version		mini	11	12	14
Endoscope diameter Ø [mm]		8.5 – 10	8.5 – 11	10.5 – 12	11.5 – 14
Depth of cap	3 mm		● 11/3a ● 11/3t	● 12/3a ● 12/3t	● 14/3a ● 14/3t
	6 mm	● mini/6a ● mini/6t	● 11/6a ● 11/6t	● 12/6a ● 12/6t ● 12/6gc	● 14/6a ● 14/6t
Max. outer diameter Ø [mm]		14.6	16.5	17.5	21

The shallow cap provides unrestricted endoscopic visibility and maneuverability and is ideal for small lesions or thin tissue areas. The deeper cap enables the user to retract and clip a larger amount of tissue.

There are three different shapes of clip teeth: a, t, gc.

type a



The "a" clip with round teeth is used if blunt compression of the tissue is intended.

type t



The "t" clip has spikes at the end of the teeth and is used if additional anchoring of the clip is intended, e.g. in hard / fibrotic tissue.

type gc



The "gc" (gastric closure) clip has elongated spikes and teeth and is only suitable for the treatment of perforations and lesions in the gastric wall.

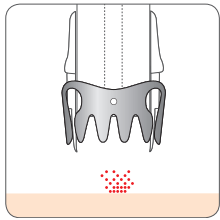
The space between the clip teeth enables micro perfusion of the tissue in situ and therefore avoids necrosis and promotes healing. All clips have the same tissue compression capabilities.

application techniques

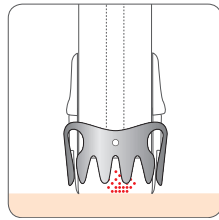
Practical application of the OTSC® System for hemostasis

Suction technique

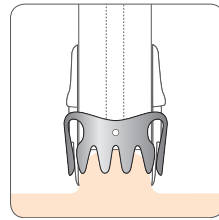
In most GI bleeding situations, tissue can be mobilized and securely pulled inside the application cap by simply applying endoscopic suction. Once the target tissue is captured inside the cap, hemostasis is achieved by turning the handwheel to release the OTSC® clip around the captured tissue.



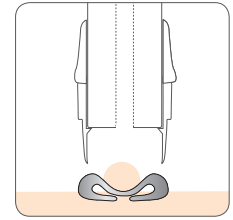
Target the lesion with the OTSC® System.



Bring the OTSC® cap in contact with the tissue.



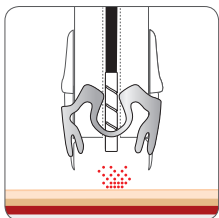
Suction the target tissue into the cap.



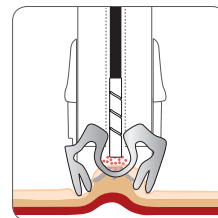
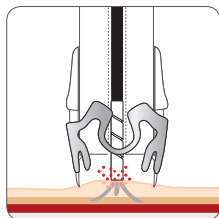
Apply the OTSC® clip by turning the hand wheel.

Anchor technique

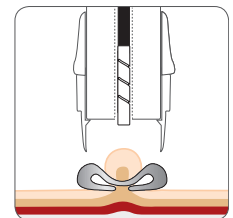
In cases of fibrotic or hard tissue (e.g. callous ulcers) or tangential application, the OTSC® Anchor can be valuable in precisely aligning target tissue with the cap opening and keeping it fixed during clip release. It may not always be possible to manipulate fibrotic tissue fully inside the cap. However, it is sufficient to pull the tissue firmly to the rim of the cap with the OTSC® Anchor, then apply the clip. The clip “jumps” slightly forward upon release and grasps the tissue in front of the cap.



Position the OTSC® Anchor and fix the tissue; align the OTSC® cap to the lesion by pulling the anchor and advancing the endoscope.



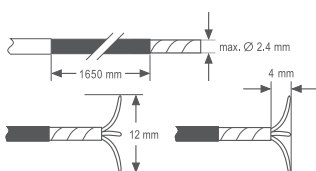
Mobilize the tip of the OTSC® Anchor shaft into the cap; anchor spikes may remain external; release the OTSC® clip.



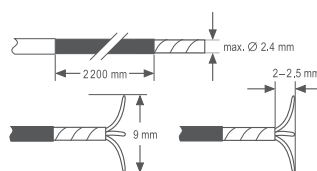
After clip application, detach the OTSC® Anchor from the tissue.

The OTSC® Anchor is available in two sizes, see figures below. In contrast to the OTSC® Anchor 165, the OTSC® Anchor 220tt has shorter prongs and is designed specifically for use in areas of the gastrointestinal tract, in which tissue is anatomically thinner, such as the colon and duodenum.

OTSC® Anchor 165 (thick tissue)



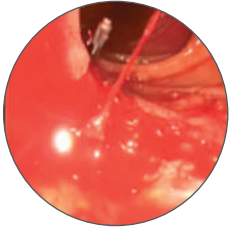
OTSC® Anchor 220tt (thin tissue)



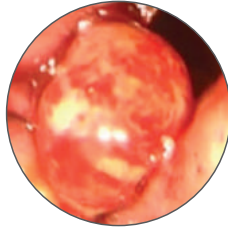
case examples

OTSC® clip placement in case of hemorrhage

Bleeding



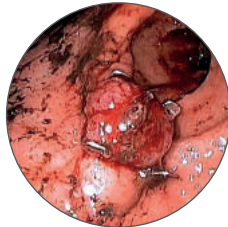
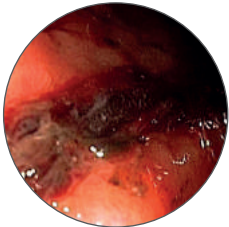
Treatment result



Spurting arterial bleeding from peptic duodenal ulcer

The images show the OTSC® treatment of a spurting arterial bleeding (Forrest Ia) from a duodenal ulcer.

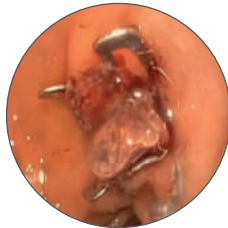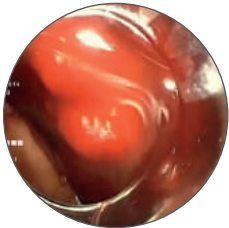
Source: Prof. Dr. P. Chiu, Department of Surgery, Prince of Wales Hospital, Hong Kong, China



Oozing bleeding from Ulcer Dieulafoy

A 70-year-old female patient was hospitalized for bronchopulmonary infection. The patient was under warfarin therapy (for recurrent deep vein thrombosis) and developed hematemesis (Hb 11.6 g/dl, INR 1.46). Upper GI endoscopy revealed an oozing bleeding from a Dieulafoy's lesion in the gastric antrum. Hemostasis was achieved successfully with an OTSC® clip. Control endoscopy was done one day later.

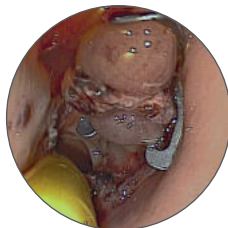
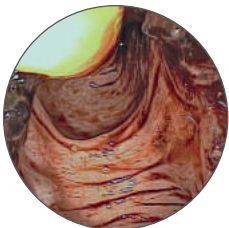Source: Prof. Dr. K. Caca & Dr. A. Schmidt, Department of Internal Medicine, Ludwigsburg Hospital, Germany



Forrest Ib bleeding from peptic duodenal ulcer

The images show the OTSC® treatment of an oozing ulcer bleeding with large vessel in the duodenum.

Source: Dr. M. Manno & Dr. P. Soriani, UOS Endoscopia Digestiva Area Nord, Azienda USL di Modena, Italy



Postoperative colonic anastomotic bleeding

Endoscopy of a 50-year-old male patient revealed anastomotic bleeding from the area of the stapling line after laparoscopic sigmoid resection. The bleeding lesion was pulled into the OTSC® cap (type 12/6t) by gentle suction. The clip was released and immediate hemostasis was achieved.

Source: Dr. T. Kratt, Department of Surgery, University Hospital Tuebingen, Germany

Follow-up

Once an OTSC® clip is successfully deployed it will stay in situ for several weeks to several months. The exact duration depends on the amount and texture of the tissue secured. The OTSC® clip will leave the GI tract naturally in the majority of cases. Occasionally, it may be overgrown by mucosa and remain in the body as a long-term implant, which is no problem because of its design and biocompatibility.

The OTSC® clip is MR conditional. Patients can be scanned safely in an MRI system after OTSC® clip placement under the following conditions: a) static magnetic field of 3 Tesla or less, b) maximum spatial gradient magnetic field of 4,000 gauss/cm (40T/m). For further details, please refer to the instructions for use. In rare cases, in which a clip removal is necessary, e.g. local complication or misplacement, the OTSC® clip can be easily removed with the Ovesco remOVE System. This gives you the option to reverse or repeat the procedure.

OTSC® is superior to other techniques in GI hemostasis

Recent study results show that the OTSC® System is particularly suitable for hemostasis.

Meta-analysis

The clinical efficacy of OTSC® has been documented in a range of peer-reviewed scientific publications over many years. A systematic literature review and meta-analysis has now confirmed this again³.

This current meta-analysis includes in total 20 clinical studies involving hemostasis by OTSC® clip application. 457 articles were screened and reviewed; 20 met the criteria to be included in the analysis covering 510 patient cases. There was one randomized-controlled trial (STING²) as well as one quasi-controlled multicentric study (FLETRock¹), which are summarized in more detail below. Both controlled studies evaluated the use of the OTSC® System for hemostasis. The results of this pooled proportion analysis showed high technical (93.0%) and clinical success (87.5%). Re-bleeding occurred in 8.3% (Table 1).

Table 1: Efficacy of the OTSC System in the treatment of GI bleeding and wall defects: a PMCF meta-analysis (Weiland et al., 2019).

Outcome	Pooled Proportion (95% CI)
Technical success	93.0% (90.2%–95.4%)
Clinical success	87.5% (80.5%–93.2%)
Re-bleeding	8.3% (5.2%–12.1%)

FLETRock

The FLETRock evaluation showed that first-line treatment of upper GI hemorrhage with the OTSC® System significantly reduced the probability of re-bleeding and re-bleeding-associated mortality compared to the state of the art, represented by the validated prognostic Rockall score¹.

The study evaluated mortality, re-bleeding and re-bleeding-associated mortality of patients, in whom the OTSC® was used as a first-line endoscopic treatment (FLET) of non-variceal upper GI bleeding. In total, 118 patients (median age of 73.5 years) were included in the multicenter evaluation and categorized into three risk groups: low risk (Rockall risk category ≤3), moderate risk (Rockall risk category 4–7) and high risk (Rockall risk category ≥8). The median Rockall score of the patient cohort was 7. Using Fisher's Exact Test, the event rates (re-bleeding, mortality after re-bleeding and mortality) observed per risk group were compared to predicted event rates (Rockall cohort). The results (Table 2) showed that treatment with the OTSC® System significantly reduced the probability of re-bleeding or continued bleeding from 24.0 to 4.9% in the moderate risk group as well as from 53.2 to 21.4% in the high risk group (p<0.001). Mortality after re-bleeding was significantly reduced from 27.9 to 10.9% in the high-risk group (p<0.011). Regarding overall mortality there was no significant difference, but a strong trend that OTSC® is more effective than former standard techniques.

Table 2: Multicenter evaluation of first-line endoscopic treatment with the OTSC in acute non-variceal upper gastrointestinal bleeding and comparison with the Rockall cohort: the FLETRock study (Wedi et al., 2018).

	Predicted probability of re-bleeding (Rockall)	Observed re-bleeding		p value
	%	% (95% CI)	n/N	
Risk-group ≤3	7.0	33 (0–71.0)	1/3	n.a.
Risk-group 4–7	24.0	4.9 (1.0–13.7)	3/61	<0.001
Risk-group 8+	53.2	21.4 (11.6–34.4)	12/56	<0.001
	Predicted probability of mortality after re-bleeding (Rockall)	Observed mortality after re-bleeding		p value
	%	% (95% CI)	n/N	
Risk-group ≤3	0.4	0 (0–70.8)	0/3	n.a.
Risk-group 4–7	7.3	1.7 (0.1–9.0)	1/60	0.121
Risk-group 8+	27.9	10.9 (4.1–22.2)	6/55	<0.011

The overall clinical success rate of the OTSC® System in non-variceal UGIB was 92.5%. In 90.8% of patient cases, first-line treatment was performed only with the OTSC® clip; in 1.7%, OTSC® and additional measures were used.

The high quality of the FLETRock evaluation was honored by the German Society for Digestive and Metabolic Diseases (DGVS). For this, Dr. Edris Wedi, main author of FLETRock, received the DGVS Endoscopy Research Award in Munich, 2018.

STING

The randomized controlled STING trial has established that OTSC® clipping is superior to former standard techniques in the treatment of severe recurrent upper GI bleeding².

The prospective multicenter STING trial determined that treatment with OTSC® is more effective than standard therapy for patients with recurrent peptic ulcer bleeding. The study included nine academic referral centers. 66 patients (adult patients with recurrent peptic ulcer bleeding following initially successful hemostasis) were randomly assigned to groups (1:1) for hemostasis with either OTSC® or standard therapy. Standard therapy was defined as hemostasis with conventional endoclips (n=31) or thermal therapy (n=2) plus injection with diluted adrenalin. The primary endpoint of the study was further bleeding, a composite endpoint of a persistent bleeding despite endoscopic therapy according to the protocol or recurrent bleeding within 7 days after successful hemostasis. In case of further bleeding, patients were allowed to cross over to OTSC® treatment. The results of the STING trial (Table 3) showed that treatment with OTSC® leads to significantly higher technical success (successful hemostasis according to protocol) than standard therapy (93.9% vs 57.6%; p=0.001). In addition, OTSC® provided significantly higher clinical success (no persistent bleeding, no recurrent bleeding) compared to standard therapy (84.8% vs 42.4%; p=0.001).

Table 3: Over the Scope Clips Are More Effective Than Standard Endoscopic Therapy for Patients With Recurrent Bleeding of Peptic Ulcers (Schmidt et al., 2018).

	Standard therapy (n=33)	OTSC® (n=33)	p value
Number of clips, median [range]	2 [1–8]	1 [1–2]	0.02
Use of thermal therapy, n (%)	2 (6.1)	0 (0)	0.492
Technical success*, n (%)	19 (57.6)	31 (93.9)	0.001
Technical failure, n (%)	14 (42.4)	2 (6.1)	0.001
Recurrent bleeding, n (%) [95% CI]	5 (16.1) [3.2–16.1]	3 (9.1) [0–18.1]	0.468
Clinical success**, n (%)	14 (42.4)	28 (84.8)	0.001
Hospital mortality, n (%)	1 (3.0)	3 (9.1)	0.613
Total mortality, n (%)	2 (6.3)	4 (12.1)	0.672

*Defined as successful hemostasis according to protocol

**Defined as no persistent bleeding, no recurrent bleeding

For their outstanding work, the authors of the prospective randomized STING trial (Schmidt et al.) were awarded with the DGE-BV Prize at the Conference of the German Society for Endoscopy and Imaging Procedures 2017.

Large multicenter trial

Analysis of 286 consecutive patient cases showed that OTSC® placement is an effective first-line treatment for endoscopic hemostasis in high-risk patients and/or lesions both in the upper and lower GI tract⁴.

In the multicenter study, prospectively collected data of patients with UGIB (n=214) and LGIB (n=72), who received OTSC® therapy at the participating sites, was evaluated. Hemostasis was performed with OTSC® as first-line endoscopic treatment in all cases. In total, 11 tertiary endoscopic referral centers took part in the study. The clinically relevant outcomes following hemostasis with OTSC® were evaluated. Technical success was defined as correct deployment of the device on the bleeding lesion and primary hemostasis as stopping of bleeding without additional endoscopic treatments. The results of Manta et al. (Table 4) showed that correct positioning of OTSC® was successful in 280 cases (technical success rate: 97.9%, 95% CI=96.2–99.6). In 270 patients, primary hemostasis was achieved with successful OTSC® deployment (primary hemostasis: 96.4%; 95% CI=94.2–98.6). The median length of hospital stay was four days.

Table 4: First-line endoscopic treatment with over-the-scope clips in patients with either upper or lower gastrointestinal bleeding: a multicenter study (Manta et al., 2018).

	Total (n=286)	UGIB (n=214)	LGIB (n=72)
Technical success (%)	280 (97.9)	208 (97.2)	72 (100)
Primary hemostasis (%)*	270 (96.4)	202 (97.1)	68 (94.4)
Early re-bleeding (%)**	12 (4.4)	9 (4.5)	3 (4.4)
Post treatment blood transfusion (%)	14 (4.9)	8 (3.7)	6 (8.3)
Hospital stay, median [range]; days	4 [3–11]	4 [2–10]	4 [3–11]
Mortality (%)	5 (1.9)	4 (2)	1 (1.5)

UGIB, upper gastrointestinal bleeding; LGIB, lower gastrointestinal bleeding

*Calculated in 280 patients, in whom technical success was achieved.

**Calculated in 270 patients, in whom primary hemostasis was achieved.

clinical evidence

Cost-effectiveness analysis

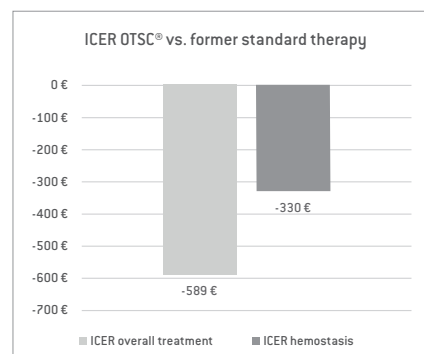
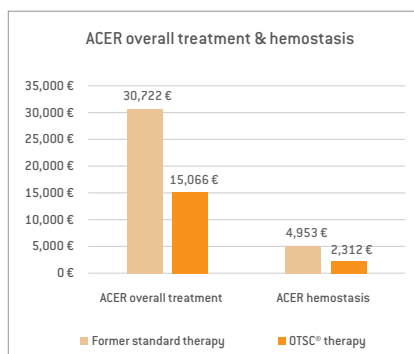
Study proves cost-effectiveness of OTSC® for hemostasis in comparison to former standard therapy⁵.

Using the clinical data of the recent randomized controlled STING trial², Kuellmer et al. analyzed the cost-effectiveness of the OTSC® System for hemostasis and compared it with the former standard therapy (conventional endoclips or thermal coagulation plus injection). For analysis, the cost-effectiveness parameters ACER (Average Cost-Effectiveness Ratio; costs incurred in order to reach a clinically successful treatment result) and ICER (Incremental Cost-Effectiveness Ratio; difference in costs of two different interventions divided by the difference in clinical outcome) were calculated from the perspective of the health care provider. The results of the analysis (Table 5) show that the ACER of OTSC® therapy is 50 % less than the ACER of former standard therapy, for overall treatment in the hospital and for endoscopic intervention alone (hemostasis): 15,066 €

vs. 30,722 € and 2,312 € vs. 4,953 €. The ICER (OTSC® therapy vs. former standard therapy) is -589 € for overall treatment and -330 € for hemostasis alone; i.e. use of the OTSC® does not incur additional costs but actually reduces the costs compared to the former standard therapy. This cost benefit results from the avoidance of follow-up costs for treatment of secondary bleeding.

Table 5: OTSC vs standard therapy of recurrent ulcer bleeding: a cost-effectiveness analysis (Kuellmer et al., 2018).

	ACER* overall treatment	ACER* hemostasis	ICER** overall treatment	ICER** hemostasis
Former standard therapy	30,721.58 €	4,952.90 €	-589.06 €	-329.86 €
OTSC® therapy	15,066.26 €	2,311.52 €		



*Average Cost-Effectiveness Ratio (ACER): average costs (in Euro) per successful hemostasis (without re-bleeding)

**Incremental Cost-Effectiveness Ratio (ICER): average incremental costs (in Euro) associated with the additional therapeutic effect of the OTSC® (successful hemostasis without re-bleeding)

The data of Kuellmer et al. demonstrate that the clinically superior OTSC® treatment is also cost-effective and even cost-reducing.

summary of clinical data

OTSC® consistently shows a clinical benefit and is superior to standard techniques in GI hemostasis

Treatment with OTSC® shows higher success rates than former standard therapy. As first-line procedure for UGIB, OTSC® prevents re-bleeding and reduces mortality.

- Patients with a Rockall score of 6 or more (higher age, comorbidities) or under anticoagulation therapy have a significantly increased risk of a complicated clinical course in GI bleeding.
- The clinical success rates of OTSC® in hemostasis are significantly superior to standard therapy (STING trial²).
- As first-line therapy, OTSC® significantly reduces re-bleeding and re-bleeding associated mortality (FLETRock evaluation¹).
- OTSC® is easy to set up and deploy and shortens time-to-hemostasis compared to other conventional clipping⁶.
- OTSC® clipping is a cost-saving procedure (cost-effectiveness analysis⁵).

» OTSC® provides a clinically relevant benefit for patients with bleeding which is scientifically proven.

OTSC® System
saving lives

6

references

Works cited in this bulletin

1. Wedi E, Fischer A, Hochberger J, Jung C, Orkut S, Richter-Schrag HJ. Multi-center evaluation of first-line endoscopic treatment with the OTSC in acute non-variceal upper gastrointestinal bleeding and comparison with the Rock all cohort: the FLETRock study. *Surg Endosc.* 2018 Jan;32(1):307-314. doi: 10.1007/s00464-017-5678-7. Epub 2017 Jun 27.
2. Schmidt A, Goelder S, Goetz M, Meining A, Lau J, von Delius S, Escher M, Hoffmann A, Wiest R, Messmann H, Kratt T, Walter B, Bettinger D, Caca K. Over the Scope Clips Are More Effective Than Standard Endoscopic Therapy for Patients With Recurrent Bleeding of Peptic Ulcers. *Gastroenterology.* 2018 Sep;155(3):674-686.e6. doi: 10.1053/j.gastro.2018.05.037. Epub 2018 May 24.
3. Weiland T, Rohrer S, Schmidt A, Wedi E, Bauerfeind P, Caca K, Khashab MA, Hochberger J, Baur F, Gottwald T, Schurr MO. Efficacy of the OTSC System in the treatment of GI bleeding and wall defects: a PMCF meta-analysis. *Minim Invasive Ther Allied Technol.* 2019 Apr 7;1-19. doi: 10.1080/13645706.2019.1590418. [Epub ahead of print].
4. Manta R, Mangiafico S, Zullo A, Bertani H, Caruso A, Grande G, Zito FP, Mangiavillano B, Pasquale L, Parodi A, Germana B, Bassotti G, Monica F, Zilli M, Pisani A, Mutignani M, Conigliaro R, Galloro G. First-line endoscopic treatment with over-the-scope clips in patients with either upper or lower gastrointestinal bleeding: a multicenter study. *Endosc Int Open.* 2018 Nov;6(11):E1317-E1321. doi: 10.1055/a-0746-8435.
5. Küllmer A, Behn J, Glaser N, Thimme R, Caca K, Schmidt A. Over-the-scope clips (OTSC) are cost-effective in recurrent peptic ulcer bleeding. *United European Gastroenterol J.* 2019 Nov; 7(9): 1226-1233
6. Kato M, Jung Y, Gromski MA, Chuttani R, Matthes K. Prospective, randomized comparison of 3 different hemoclips for the treatment of acute upper GI hemorrhage in an established experimental setting. *Gastrointest Endosc.* 2012 Jan;75(1): 3-10. doi: 10.1016/j.gie.2011.11.003.

Further reading

7. Kobara H, Mori H, Nishiyama N, Fujihara S, Okano K, Suzuki Y, Masaki T. Over-the-Scope Clip System: A review of 1517 cases over 9 years. *J Gastroenterol Hepatol.* 2019 Jan;34(1):22-30. doi: 10.1111/jgh.14402. Epub 2018 Aug 16.
 8. Tran P, Carroll J, Barth BA, Channabasappa N, Troendle DM. Over the Scope Clips for Treatment of Acute Non-Variceal Gastrointestinal Bleeding in Children is Safe and Effective. *J Pediatr Gastroenterol Nutr.* 2018 Oct;67(4):458-463. doi: 10.1097/MPG.0000000000002067.
 9. Asokkumar R, Soetikno R, Sanchez-Yague A, Kim Wei L, Salazar E, Ngu JH. Use of over-the-scope-clip (OTSC) improves outcomes of high-risk adverse outcome (HR-AO) non-variceal upper gastrointestinal bleeding (NVUGIB). *Endosc Int Open.* 2018 Jul;6(7):E789-E796. doi: 10.1055/a-0614-2390. Epub 2018 Jul 4.
 10. Martínez-Alcalá A, Moenkemüller K. Emerging Endoscopic Treatments for Non-variceal Upper Gastrointestinal Hemorrhage. *Gastrointest Endosc Clin N Am.* 2018 Jul;28(3):307-320. doi: 10.1016/j.giec.2018.02.004. Epub 2018 Apr 12.
 11. Raimundo Fernandes S, Lopes J, Isabel Valente A. Duodenal Diverticular Bleeding Managed Using an Over-the-Scope Clip. *Clin Gastroenterol Hepatol.* 2018 Mar;16(3):A36. doi: 10.1016/j.cgh.2017.05.040. Epub 2017 Jun 7.
 12. Cahyadi O, Caca K, Schmidt A. Over-the-scope clip is an effective therapy for postbanding ulcer bleeding after initially successful transjugular intrahepatic portosystemic shunt therapy. *Endoscopy.* 2017 Oct;49(10):E258-E259. doi: 10.1055/s-0043-115890. Epub 2017 Jul 31.
 13. Brandler J, Baruah A, Zeb M, Mehfooz A, Pophali P, Wong Kee Song L, AbuDayyeh B, Gostout C, Mara K, Dierkhising R, Buttar N. Efficacy of Over-the-Scope Clips in Management of High-Risk Gastrointestinal Bleeding. *Clin Gastroenterol Hepatol.* 2018 May;16(5):690-696.e1. doi: 10.1016/j.cgh.2017.07.020. Epub 2017 Jul 26.
 14. Robles-Medrandá C, Puga-Tejada M, Ospina J, Valero M, Pitanga Lukashok H. Over-the-scope clip in the management of fibrotic esophageal variceal bleeding (with video). *Endosc.* 2017 Oct;86(4):732-733. doi: 10.1016/j.gie.2017.04.027. Epub 2017 Apr 29.
 15. Lamberts R, Koch A, Binner C, Zachaeus M, Knigge B, Bernhardt M, Halm U. Use of over-the-scope clips (OTSC) for hemostasis in gastro-intestinal bleeding in patients under antithrombotic therapy. *Endosc Int Open.* 2017 May;5(5):E324-E330. doi: 10.1055/s-0043-104860.
 16. Probst RL, Kratt T. A randomized comparative trial of OTSC and Padlock for upper GI hemostasis in a standardized experimental setting. *Minim Invasive Ther Allied Technol.* 2017 Apr;26(2):65-70. doi: 10.1080/13645706.2017.1291523. Epub 2017 Feb 24. PubMed PMID: 28350273.
 17. Schmidt A, Caca K. Therapie der nicht-varikoesen oberen gastrointestinalen Blutung. *Falk Gastro-kolleg 3/2017.*
 18. Ovesco Endoscopy AG. Superiority of the OTSC® System in the treatment of upper GI bleeding. DGE-BV 2017 Symposium report.*
- * Videos, presentations, interviews and the report of the DGE-BV 2017 Symposium can be found on the Ovesco website (www.ovesco.com).

Use the attached QR code for detailed information on the symposium and to see further clinical cases (videos) on hemostasis with the OTSC® System.



Educational scope:

In this booklet we offer information for health care professionals as an educational tool and in good faith. This information is offered without warranty of any kind although it has been thoroughly reviewed and is considered to be useful and precise at the time of publication.

The authors and manufacturers shall not be held responsible for any loss or damage arising from its use. We refer to the instructions for use coming with each device containing valid directives.

Other clinical bulletins:

- OTSC® System for Bariatric Surgery (vol. 1)
- OTSC® Proctology in Anorectal Fistula (vol. 2)

o o o | o v e s c o
innovation in scope

Ovesco Endoscopy AG
Friedrich-Miescher-Strasse 9
72076 Tuebingen
Germany

Phone +49 (0) 70 71.96 528-160
Fax +49 (0) 70 71.96 528-260
E-mail service@ovesco.com

www.ovesco.com

Ovesco Endoscopy USA, Inc.
120 Quade Drive
Cary, NC 27513
U.S.A.

Phone +1 919 651 9449
Fax +1 408 608 2077

E-mail customerservice@ovesco-usa.com